



Ayurvedic Management of Primary Open Angle Glaucoma

Archana V K¹, Vaghela DB²

¹PhD Scholar, ²Associate Professor, Institute for Post Graduate Teaching and research in Ayurveda, Gujarat Ayurved University, Jamnagar

ABSTRACT

Primary open angle glaucoma (POAG) is a chronic, progressive optic neuropathy causing irreversible vision loss. Currently available conventional options have certain limitations; considering which options from alternative resources are being searched. Ayurvedic treatment principles which are targeted towards the basic pathophysiology can play a significant role in the integrated management of this disease. In this case study, Ayurvedic treatment was done along with conventional treatment. A male patient aged 58 years visited *Shalakaya - Netra* OPD complaining defective vision for both distance and near since six months. He was a diagnosed case of POAG since 5 years and was on Latanoprost eye drops once daily. He was given *Deepana, pachana, anulomana, Shiro virechana* and six sittings of *Tarpana* with *Shigru Arka*. He was also taking *Rasayana yoga* (~herbomineral formulation with rejuvenating properties) for three months. There was improvement in visual acuity in both eyes along with significant reduction of intraocular pressure. Visual field analysis showed improvement in retinal sensitivity. Blood parameters showed no significant changes in hematological and biochemical parameters except for reduction in Triglyceride value from 205 mg/dl to 153 mg/dl. Thus, it can be concluded that Ayurvedic approach is helpful in giving a complimentary treatment protocol for Primary open angle glaucoma.

Key words: Ayurveda, *Nasya*, Primary open angle glaucoma, *Rasayana*, *Tarpana*.

INTRODUCTION

Primary open angle glaucoma (POAG) can be considered as a chronic progressive optic neuropathy that is accompanied by a characteristic cupping and atrophy of the optic disc, visual field loss and open angles and no obvious causative ocular or systemic conditions¹. It is the second leading cause of blindness worldwide². The characteristic optic nerve cupping results from slowly progressive loss of retinal ganglion cells and their neurons which is irreversible. This disease has a hereditary component and becomes more prevalent with age. Since the disease is slowly progressive and asymptomatic until late in its course, affected individuals can develop severe damage before seeking medical care.

Since IOP is the only modifiable risk factor to prevent the progress of the disease, most of the treatment modalities are directed towards its reduction. But the neurodegeneration continues even after lowering IOP and this has led to the exploration of neuroprotective treatment strategies. Ayurveda has potent treatment strategies in site specific neuroprotection. The progressive visual function loss can be successfully tackled and controlled by using *Chakshushya Rasayanas* which act upon the pathogenesis of the disease and strengthens the ocular tissues. An ideal anti glaucoma treatment should sustain sufficient reduction in intraocular pressure for longer duration; preserve visual fields, devoid of side effects and at the same time compatible with currently available treatment strategies³. In this case of POAG, Ayurvedic treatment was done along with conventional treatment.

CASE REPORT

A 58 years old moderate built, male working as a tailor reported to the OPD on 16-06-2016 complaining of gradual painless diminution of distant as well as near vision for the last two years and was severe since 2 months. He also had side vision difficulty more pronounced in his right eye, delayed dark adaptation and frequent changes in near vision glasses since 2 years. He was a known case of POAG diagnosed since 5 years, using topical Latanoprost eyedrops. He was also diabetic and hypertensive and was on oral

hypoglycemic and anti-hypertensive medicines since last 5 years. On his visit to the OPD, he had good glycemic control. He was a chronic smoker, had a habit of smoking for the past few years (about 10 cigarettes per day), which he stopped about a year before the day of assessment. There was family history of POAG (Mother with end stage optic atrophy). He came to OPD enquiring Ayurvedic solutions for his condition. Ayurvedic treatment was started on 22.06.2016 after detailed assessment of his visual functions and optic nerve head characteristics.

Clinical findings

He was afebrile. Pulse was 75/minute. Respiratory Rate was 18/minute and Blood Pressure was 130/90 mmHg. Systemic examination of respiratory, circulatory, digestive systems etc were within normal limits.

Visual examination

Distant visual acuity by Snellen's chart was 6/18 OD and 6/12p O S. Best corrected visual acuity in both eyes was 6/12. Correction for Right eye was +1.00 cylindrical at 145 degree and for Left eye was +1.00 spherical. Near vision Unaided was N10 in both eyes and with an addition of +2.5 Ds became N6.

Ocular examination

Eyelids, Conjunctiva, Sclera and cornea were normal in both eyes. Anterior chamber was deep (Grade 4 by Van Herick method using Slit lamp). Pupils were of normal size and normal reaction. Both lens had immature senile cataract (Grade- Cortical -1 by LOCS [Lens Opacities Classification System] III). Intra Ocular Pressure [IOP] by Schiottz Tonometry was 17.3 mm Hg in both eyes. Direct Ophthalmoscopy revealed Advanced POAG in both eyes. Visual field assessment using medmont perimeter showed severe glaucomatous field changes with right eye having only central ten degree visual field and left eye having lower arcuate field defect with advancing superior arcuate defect.

Dashavidha pareeksha (~Tenfold Examination)

His *Prakriti* was *Vatakapha*. *Vikriti* was *Vata pradhana Tridosha* with involvement of *Prana* and *Vyana Vayu*, *Alochaka Pitta* and *Tarpaka Kapha*. He was in *Vridhavastha* (~old age). His *Satwa* (~psyche), *Sara* (~excellence of tissues), *Samhanana* (~Compactness of organs), *Ahara shakti* (~power of food intake and digestion), *Satmya* (~suitability) and *Pramana* (~measurements of body organs) were of *Madhyama* (~moderate) level. His *Vyayama shakti* (~power of performing exercises) was *avara* (poor).

Ashtavidha pareeksha (~Eightfold Examination)

His *Nadi* (~pulse) was *dhruta* (fastly pulsating), *Mutra* (urine) was of *prakrita varna* (normal colour) *Mala* (stool) was *rooksha* and *badha* (Hard and constipated), *Jihwa* (tongue) had *upalepa* (coated), *Shabda* (voice) was *spashta* (clear), *Sparsha* (Touch) *Anushna sheeta* (~normal temperature), *Akrithi* (body built) was *Madhyama* (~moderate) and *Drik* (vision) was *Heena* (reduced).

Sroto pareeksha (~Examination of body channels)

Rasavaha, *Raktavaha*, *Mamsavaha* and *medovaha srotas* (~blood circulating and supporting channels of aqueous pathway and microvasculature of optic nerve) are involved and the pathology is *Margavarodha* and *Vimarga gamana* (~ obstruction and flowing abnormal) possibly manifested as elevated IOP and optic nerve and retinal nerve fibre layer degeneration.

Diagnostic assessment

Laboratory investigations before treatment revealed Hb- 13.1 gms %, FBS - 99mg/dl, Serum cholesterol- 138 mg/dl, Serum triglycerides-205mg/dl. Other hematological findings were within normal limits. Visual acuity for near and distant vision was done using Snellens near vision chart and Snellens distant vision box. Detailed assessment of anterior chamber of eye was done with slit lamp biomicroscopy with anterior chamber angle depth assessed using Van Herick's method. IOP measurement was done with Schiottz Tonometer. Fundus photo was taken, which confirmed the diagnosis of Advanced POAG in both eyes [Figure - 1&2]. Visual field analysis showed preserved central field in right eye and double arcuate defect in left eye [Figure - 3, 4, 5& 6].

Figure 1 & 2 – Optic disc of Right and Left eye respectively

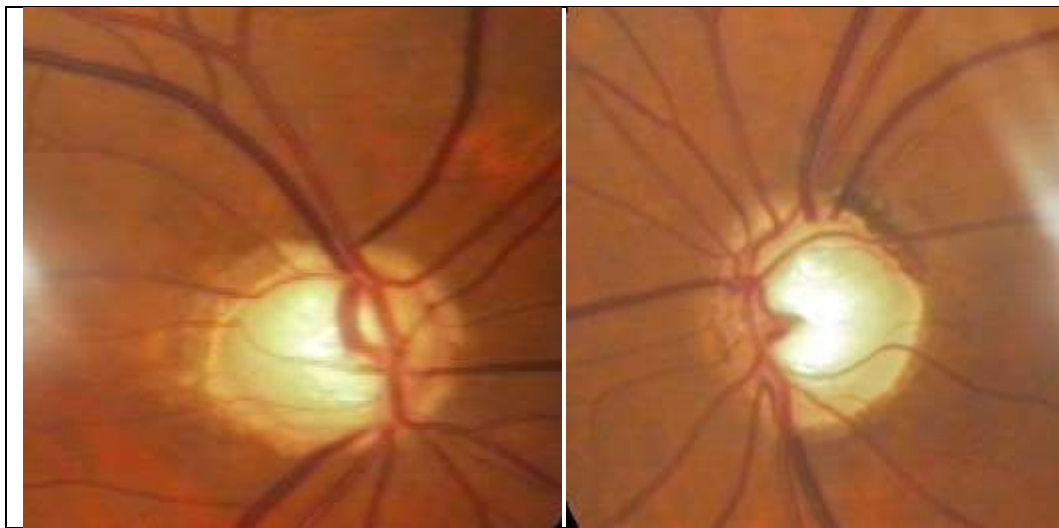


Figure 3 & 4- Visual field of Right eye before and after treatment respectively

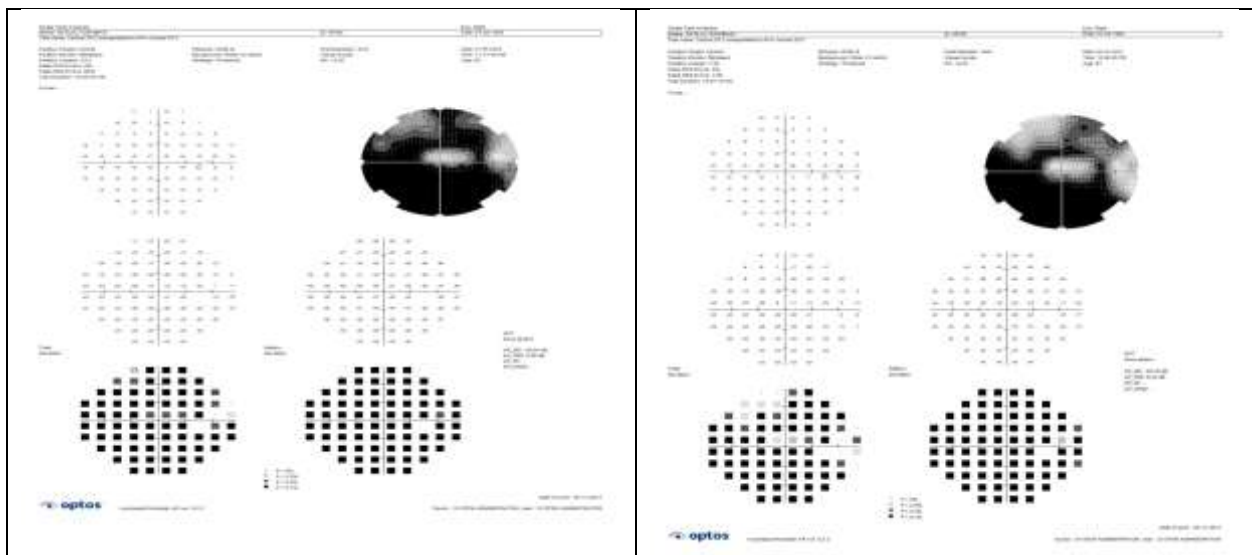
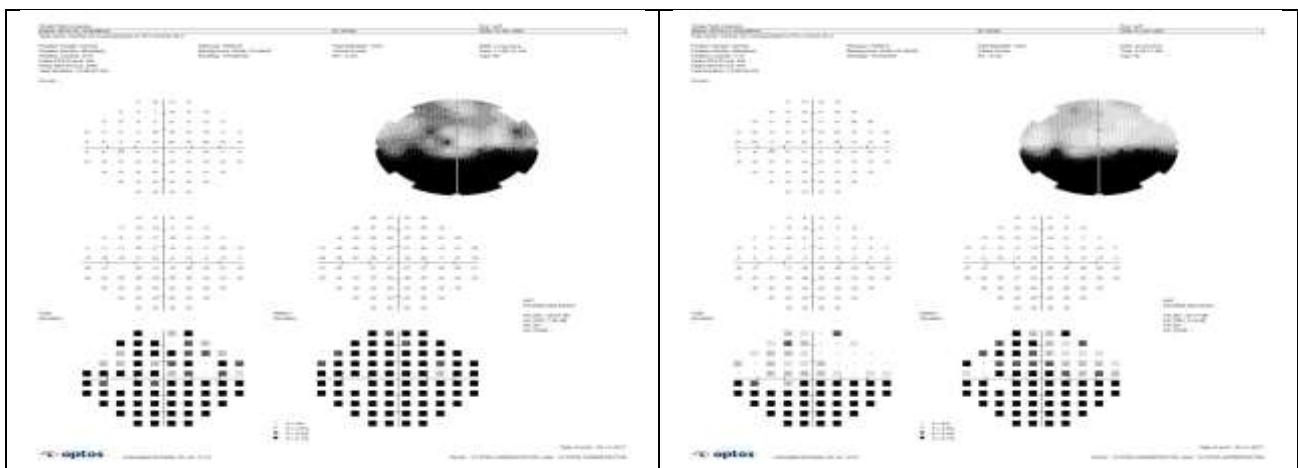


Figure 5 & 6- Visual field of Left eye before and after treatment respectively



Therapeutic intervention: The interventions are tabulated in Table-1.

Sl. No.	Procedure	Medicine used	Duration	Posology
1	<i>Deepana, pachana, anulomana</i>	<i>Erandabhrishta Hareetaki</i> ⁴	5 days	6 gms with hot water at bed time.
2.	<i>Marsha nasya</i>	<i>Anutaila</i> ⁵	Next 7 days	10 drops instilled in each nostril at morning.
3.	<i>Tarpana</i>	<i>Shigru Arka</i> ⁶	After a gap of one week of Nasya for seven days.	25ml over eyes bounded with a paste of black gram powder for 25 minutes.
4.	<i>Shamana yoga</i>	<i>Rasayana yoga</i>	Started after <i>deepana, pachana & anulomana</i> and was continued for 3 months along with other procedures.	2 gms with half teaspoon <i>Madhu</i> and one teaspoon <i>Ghrita</i> at bed time.

Tarpana with *Shigru Arka* was done twice a month for 1 week with a gap of 1 week in between and continued for 3 months.

Table-2 Improvement in vision

	Right Eye		Left Eye	
	Before Treatment.	After Treatment.	Before Treatment.	After Treatment.
DV	6/18	6/12	6/12p	6/12
BCVA	6/12	6/9	6/12	6/9
PH	6/18	6/12	6/12	6/12
NV (BC)	N6	N6	N6	N6

D.V- Distant Vision; B.C.V.A- Best Corrected Visual Acuity; P.H-Pin Hole Correction; N.V-Near Vision; BC- Best corrected.

Table -3 Reduction in Intraocular pressure

	Right Eye		Left Eye	
	Before Treatment	After Treatment	Before Treatment	After Treatment
IOP	17.3mm Hg	17.3mm Hg	14.6mm Hg	14.6mm Hg

IOP- Intraocular pressure

Table-4 Contents of *Rasayana Yoga*:

Sr. No.	Drug	Scientific/ Botanical Name	Parts used	Quantity
1	<i>Suvarna Makshika</i>	Chalcopyrite	<i>Bhasma</i>	60 mg
2	<i>Abhraka</i>	Mica	<i>Bhasma</i>	60 mg
3	<i>SaptamrutaLauha</i>	<i>Lauha</i> Formulation	<i>Choorna</i>	250 mg
4	<i>Rasayanachurna</i> <i>Guduchi</i> <i>Gokshura</i> <i>Amalaki</i>	<i>Tinospora cordifolia</i> Willd. <i>Tribulus terrestris</i> Linn. <i>Emblica officinalis</i> Gaertn.		gm

RESULTS:

There was improvement in visual acuity and IOP in both eyes [Table 2]. Fundus examination findings were unchanged with no progression of cupping [Figure 4&5]. The only significant blood parameter change was in Serum Triglyceride level from 205 mg/dl to 153 mg/dl. Visual field analysis showed mild improvement in retinal sensitivity with no further progression of defects. Visual acuity and IOP was maintained during the follow-up period also.

DISCUSSION:

The pathogenesis of POAG can be described at two level viz. at the level of aqueous outflow system and at the level of optic nerve head and retina. As per the mechanical theory, the supportive structure of optic nerve, lamina cribrosa gets compressed in POAG patients⁷ either due to raised IOP or inherent weakness of the tissue leading to distortion and damage to axons. This can also cause ischemia/ hypoxia by compressing the capillaries supplying these axons thus disrupting normal axoplasmic flow and cell death. Vascular theory suggests impaired auto regulation of Optic nerve vessels. The Ayurvedic interpretation of the mechanical and vascular mechanisms refers to *Prana* and *Vyana Vayu dushti*⁸.

Impaired *autoregulation* occurs due to *Prana Vayu dushti* resulting in vasospasm (*Samkocha* and *Vikasa*-abnormal constriction and dilatation) and causes *Vyana Vayu dushti* (factor for fluid transport in body) and ischemia. This reduction in blood circulation and nutrients indicates *srotavarodha* at the level of *rasayanis* (obstruction in microchannels providing nourishment) and results in *dhatu kshaya* (tissue loss)⁹. The hypoxia at ONH indicates *pranavaha srotodushti*. As the circulation of *rasa-rakta* (the vehicle of nutritional factors for dhatus, the structural elements) is impaired *rasavaha srotodushti* leading to *dhatu kshaya* (degeneration) can be considered as a component of pathogenesis.

Srotorodha also occurs in aqueous outflow channels as a result of *dhatwagni mandhya* causing *malasanchaya*. *Ama* or *malasamchaya* means deposition of unwanted or waste materials in the body tissues which disturbs the homeostasis, ultimately leading to functional and structural damage. Normal outflow of aqueous depends upon the integrity of outflow structures especially in the Trabecular meshwork (TM) and determines the IOP. In POAG, there is increased extracellular matrix (ECM) deposition (*Malasanchaya*) in TM and cellular components of ciliary body caused by decreased activity or Matrixmetalloproteinases (*dhatwagnimandhya*). This imparts resistance to the fluid passing through it (*Srotorodha*) causing *Margavarodhajanya Vata kopa* resulting in elevated IOP.

The signalling mechanisms of immune system initiated by high IOP, ischemia, and excessive excitatory amino acids can cause neuronal cell death¹⁰. Auto antibodies against Glycosaminoglycans which maintain the structural and functional at ONH were found in eyes of POAG patients. A lack of cell-mediated immunity has been observed as leukocyte migration inhibition is found in POAG patients. These all implies *Vyadhikshamatwahani*¹¹ leading to progressive damage of optic nerve.

Thus majority of the risk factors and pathological mechanisms involved in pathogenesis of glaucoma indicate the role *Vata* dysfunction which regulates the activities of other two doshas viz. *Pitta* and *Kapha*. In the later stages of glaucoma all three *doshas* turn abnormal while *Vata* continue to play a predominant role. *Agnimandya*, *malasamchaya*, *margavarodha*, *pranavaha* and *rasavaha srotodushti* and *Vyadhikshamatwahani* also seem to play a significant role in glaucomatous damage¹². All these aspects should be kept in mind while selecting the therapeutic interventions.

Deepana, *Pachana* and *Anulomana* was done to relieve *agnimandhya* both at *Koshta* (gastrointestinal) and *Dhatu* (tissue) level and to bring *Vata doshanulomana* (homeostasis of *Vata*). Having *Samagni* is the base for being healthy and to have proper metabolism and absorption of the drug. *Erandabhrishta Hareetaki* was used for this purpose as can achieve all the above. *Shiro virechana* was done with *Anu taila* owing to its properties of *Indriyasroto pravesa* i.e. permeating into minute channels and *margavishodhana* (removes obstruction).^[22] *Tarpana* with *Shigru Pallava Arka* was selected since it is said to be *Srotoshodhaka* which helps to remove the *Marga-Avarodha* and *Sanga* & also *Chakshusya* in nature. *Arka* is the most potent preparation with less chance of irritation and allergies. *Rasayana yoga* is an experience based herbo mineral powder [Table 3] being practiced at Institute for Post Graduate Teaching and Research in Ayurveda, Jamnagar, containing *Chakshushya* and *Rasayana* drugs. The ingredients were having immunomodulatory, adaptogenic, antioxidant and neuroprotective activities. Honey and ghee which also had *Chakshushya* properties was added to the combination for its targeted and synergistic action on ocular tissue. Overall effect of the therapy was removal of obstruction and improved nourishment of ocular tissues which resulted in reduction of IOP, improved retinal sensitivity and vision.

Patient was using conventional anti-diabetic and anti-hypertensive drugs throughout these days of Ayurvedic management. No adverse events were reported during the study and follow-up period. This indirectly reveals that the conventional and traditional drugs concomitantly used in this case are not interacting with each other.

CONCLUSION:

Thus, it can be concluded that Ayurvedic approaches are helpful in managing degenerative diseases like Primary open angle glaucoma. This study also emphasizes that Ayurveda can play a significant role in the integrated management of this condition. Considering such beneficial activities of Ayurveda approaches; there is a need to undertake collaborative researches to generate evidences at large scale.

REFERENCES

1. Brandt JD: Corneal thickness in glaucoma screening, diagnosis and management, *Curr Opin Ophthalmol* 15: 85, 2004.
2. Quigley H, Broman A: Number of people with glaucoma worldwide in 2010 and 2020, *Br J Ophthalmol* 90: 262, 2006.
3. https://www.researchgate.net/profile/Narayanam_Srikanth/publication/215556738_Select_Research_leads_in_Ayurvedic_Ophthalmology/links/07f45cae4043cfba60ee3e53/Select-Research-leads-in-Ayurvedic-Ophthalmology.pdf?origin=publication_list
4. Sharma P V, Classical uses of medicinal plants, 1st edition, Chaukhamba Sanskrit Sansthan, Varanasi, 1996.
5. Arunadatta, commentator, Ashtanga Hridaya, Sutra sthana, Nasyavidhi Adhyaya, 20/38, Reprint, Chaukhamba Sanskrit Sansthan, Varanasi, 2011, 294
6. Dr. Indradev Tripathi, commentator, Hindi commentry, Arka Prakasha, Triteeya Shataka, 2nd edition, Chaukhambha Krishnadas Acedemy, Varanasi, 2006, 48.
7. Quigley HA, Hohman RM, Addicks EM *et al.*: Morphologic changes in the lamina cribrosa correlated with neural loss in open-angle glaucoma, *Am J Ophthalmol* 95:673, 1983.
8. Dalhana, commentator, Sushruta Samhita, Sutrasthana, Doshadhatumalakshayavidhi vijnaneeyam Adhyaya, 15/1, Reprint, Chaukhamba Sanskrit Sansthan, Varanasi, 2014, 69.
9. Agnivesha: commentator, Charaka Samhita, Vimanasthana, Chapter 5/25, Reprint, Chaukhamba Sanskrit Sansthan, Varanasi, 2011.
10. Mona Pache, and Josef Flammer: A Sick Eye in a Sick Body? Systemic Findings in Patients with Primary Open-angle Glaucoma. *Survey of Ophthalmology* Volume 51, 3 May–June 2006.
11. Dalhana, commentator, Sushruta Samhita, Sutrasthana, Doshadhatumalakshayavidhi vijnaneeyam Adhyaya, 15/20, Reprint, Chaukhamba Sanskrit Sansthan, Varanasi, 2014, 71.
12. Kumar M, Varshney S, Maurya O. Pathogenesis of glaucoma: integration of biomedical and ayurvedic perspectives. [Http://www.jreim-ayushjournal.com/?mno=191784](http://www.jreim-ayushjournal.com/?mno=191784) [access: december 11, 2017].